INSELSPITAL
Universitätsklinik für
Viszerale Chirurgie und Medizin

Schlingenpolypektomie/EMR (Kolon)

Freitagsfortbildung, 03.09.2021

Kolonopolypen

- Kolorektales Karzinom: 3. häufigste Karzinom bei Männern und 2. bei Frauen

- Inzidenz und Mortalität: Männer > Frauen

- Inzidenz und Mortalität: reduziert in den letzten Jahrzehnten
  - **Vorsorgekoloskopie -> Polypenentfernung**
  - Estdiagnose in früherem Stadium
  - Effektive primäre und adjuvante Therapie

INSELSPITAL
Universitätsklinik für
Viszerale Chirurgie und Medizin

Qualitätsanspruch bei Screeningkoloskopien

European Society of Gastrointestinal Endoscopy (ESGE)

- Gute Vorbereitung (bowel cleansing)
- Zökumintubation (mind. 90%)
- Polypendetektionsrate (Adenoma detection rate - ADR)
- Polypenbergungsrate (Retrieval rate of polyps - mind. 90%)
- Rückzugszeit (mind. 6 Minuten)

Bauchzentrum
BERN

Polypenevaluation

RECOMMENDATION

ESGE recommends that gross morphology of polyps should be described using the Paris classification system and sized in millimeters. (Moderate quality evidence; strong recommendation.)

INSELSPITAL
Universitätsklinik für
Viszerale Chirurgie und Medizin

Polypenevaluation
Paris-Klassifikation

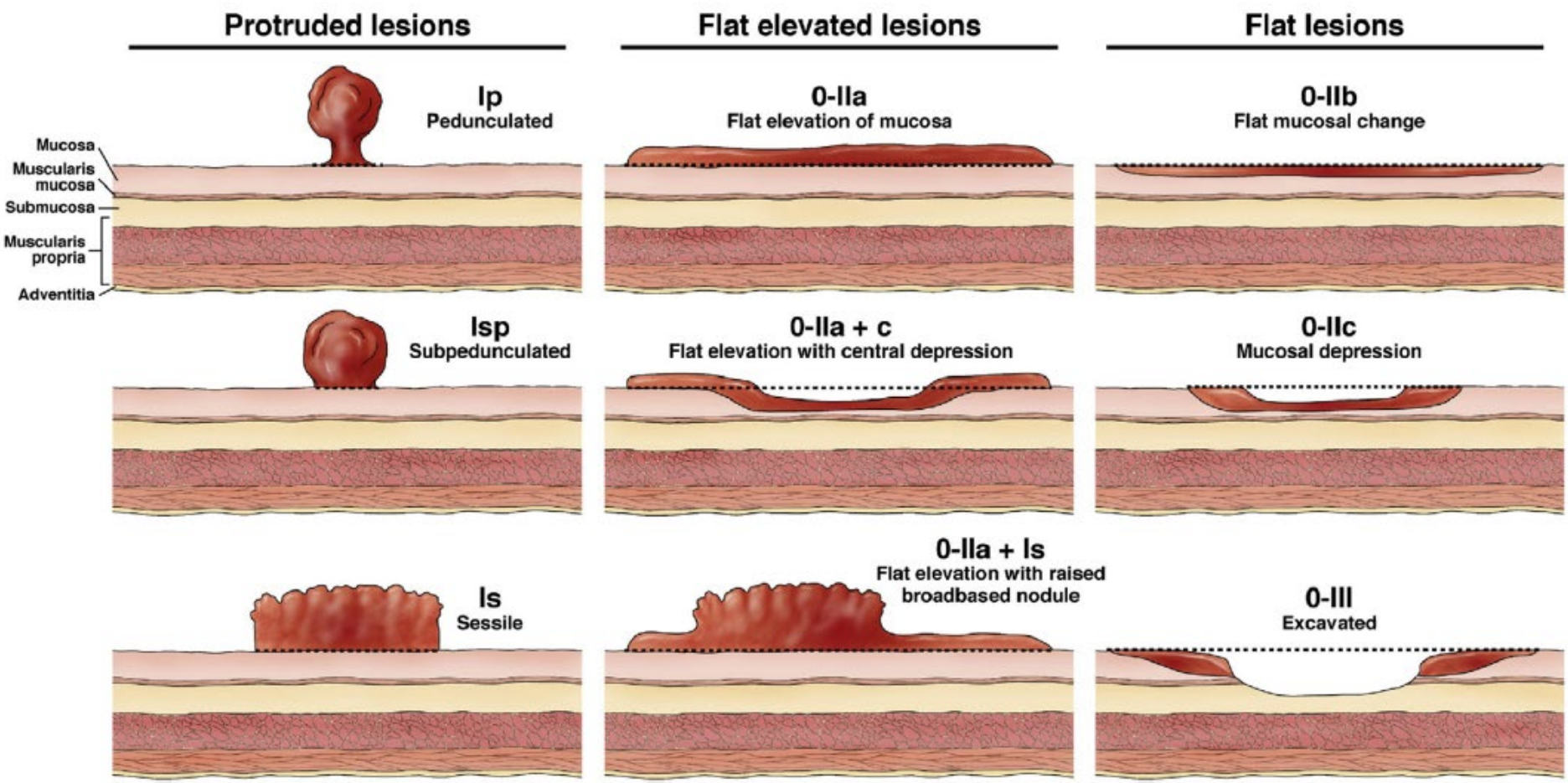

Bauchzentrum
BERN

Polypenevaluation

Advanced imaging technologies

- Norrow Band Imaging (NBI)
- Flexible Spectral Imaging Color Enhacement (FICE)
- Chromoendoscopy (methylene blue, indigo carmin)
- Image Enhanced Endoscopy (i-SCAN)
- Blue Laser/Light Imaging (BLI)

INSELSPITAL
Universitätsklinik für
Viszerale Chirurgie und Medizin

Polypenevaluation
Kudo Klassifikation

Type	Schematic	Endoscopic	Description	Suggested Pathology	Ideal Treatment
I	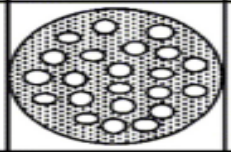		Round pits.	Non-neoplastic.	Endoscopic or none.
II	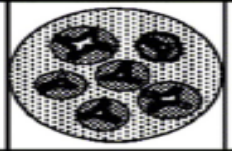	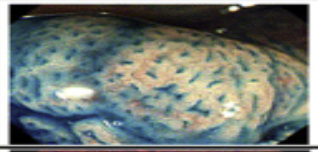	Stellar or pap-illary pits.	Non-neoplastic.	Endoscopic or none.
III_S	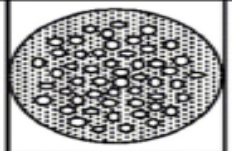		Small tubular or round pits that are smaller than the normal pit	Neoplastic.	Endoscopic.
III_L			Tubular or roundish pits that are larger than the nor-mal pits.	Neoplastic.	Endoscopic.
IV			Branch-like or gyrus-like pits.	Neoplastic.	Endoscopic.
V_I			Irregularly ar-ranged pits with type IIIs, III_L, IV type pit patterns.	Neoplastic (invasive).	Endoscopic or surgical.
V_N	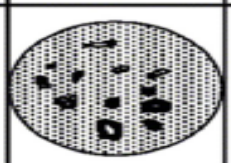		Non-structural pits.	Neoplastic (massive submucosal invasive).	Surgical.

Bauchzentrum
BERN

INSELSPITAL
Universitätsklinik für
Viszerale Chirurgie und Medizin

Polypenevaluation
NICE Klassifikation

NBI International Colorectal Endoscopic (NICE) Classification*

	Type 1	Type 2	Type 3
Color	Same or lighter than background	Browner relative to background (verify color arises from vessels)	Brown to dark brown relative to background; sometimes patchy whiter areas
Vessels	None, or isolated lacy vessels coursing across the lesion	Brown vessels surrounding white structures**	Has area(s) of disrupted or missing vessels
Surface Pattern	Dark or white spots of uniform size, or homogeneous absence of pattern	Oval, tubular or branched white structure surrounded by brown vessels**	Amorphous or absent surface pattern
Most likely pathology	**Hyperplastic**	**Adenoma*** **	**Deep submucosal invasive cancer**
Examples	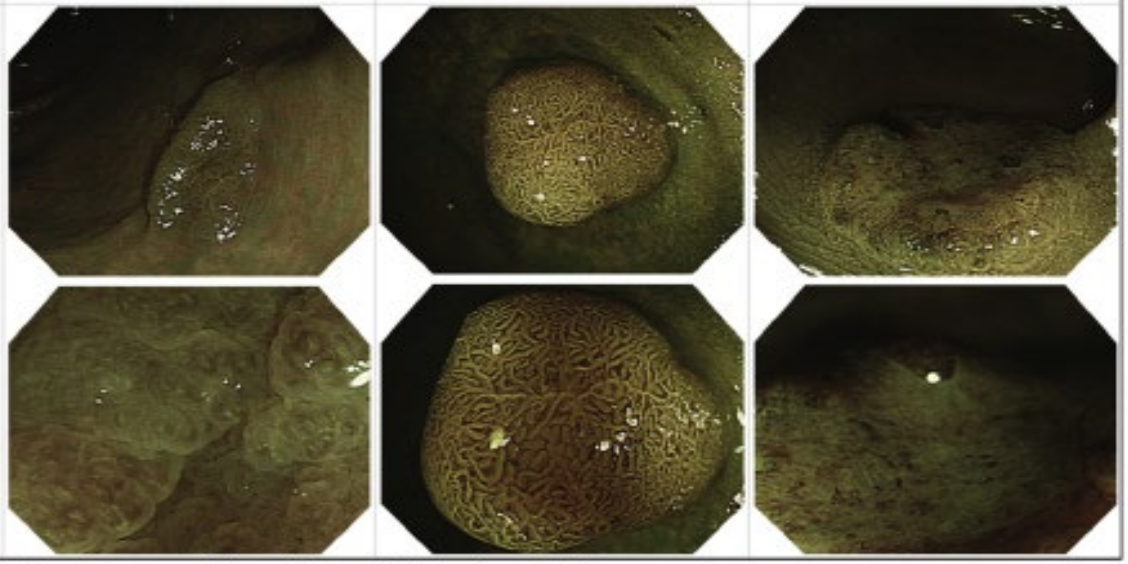		

* Can be applied using colonoscopes with or without optical (zoom) magnification

** These structures (regular or irregular) may represent the pits and the epithelium of the crypt opening.

*** Type 2 consists of Vienna classification types 3, 4 and superficial 5 (all adenomas with either low or high grade dysplasia, or with superficial submucosal carcinoma). The presence of high grade dysplasia or superficial submucosal carcinoma may be suggested by an irregular vessel or surface pattern, and is often associated with atypical morphology (e.g., depressed area).

Bauchzentrum
BERN

Polypektomie

RECOMMENDATION

ESGE recommends that all polyps be resected except for diminutive (≤ 5 mm) rectal and rectosigmoid polyps that are predicted with high confidence to be hyperplastic. (High quality evidence; strong recommendation.)

Polypektomie

- **Diminutive Polypen, bis 5 mm**

RECOMMENDATION

ESGE recommends cold snare polypectomy (CSP) as the preferred technique for removal of diminutive polyps (size ≤5 mm). This technique has high rates of complete resection, adequate tissue sampling for histology, and low complication rates. (High quality evidence; strong recommendation.)

RECOMMENDATION

ESGE recommends against the use of cold biopsy forceps (CBF) excision because of high rates of incomplete resection. In the case of a polyp sized 1–3 mm where cold snare polypectomy is technically difficult or not possible, cold biopsy forceps may be used. (Moderate quality evidence; strong recommendation.)

Polypektomie

- **Diminutive Polypen, bis 5 mm**

Polypektomie: Cold Snare vs. Forceps

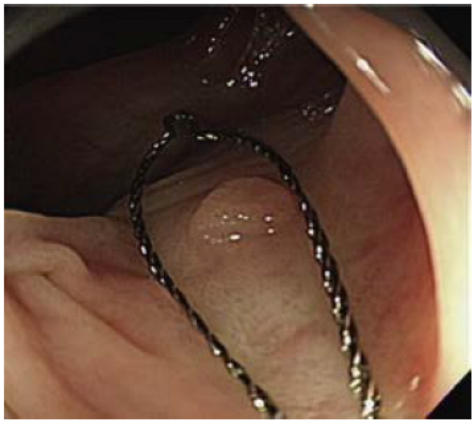

Kim JS et al Gastrointest Endosc. 2015 Mar;81(3):741-7

- Prospective RCT, single center university hospital
- 137 pat. (≥1 polyp) with 145 polyps (≤ 7mm) randomized CSP vs. CFP, additional EMR

- Overall complete resection rate: 96.6% (57/59) vs. 82.6% (57/69); p=0.011
- Complete resection rate for polyp ≤ 4mm: 100% vs. 96.9%; p=1.000

- Tissure retrieval failure: CSP 3/70 (4.3%) va. CFP 0/75 (0%)

Polypektomie

- **Kleine Polypen, 6 - 9 mm**

RECOMMENDATION

ESGE recommends snare polypectomy for sessile polyps 6–9 mm in size. ESGE recommends against the use of biopsy forceps for resection of such polyps because of high rates of incomplete resection. (High quality evidence; strong recommendation.)

Vorteile kalte vs. warme Polypektomie:

- Niedriger Risiko für Blutung
- Niedriger Risiko für Postpolypektomie-Syndrom
- Kürzer Untersuchungszeit

Polypektomie

- **Sessile Polypen 10 – 19 mm**

RECOMMENDATION

ESGE suggests hot snare polypectomy (HSP) (with or without submucosal injection) for removal of sessile polyps 10 – 19 mm in size. In most cases deep thermal injury is a potential risk and thus submucosal injection prior to HSP should be considered. (Low quality evidence; strong recommendation.)

Unterspritzung:

- «En block» Polypektomie
- Weniger thermische Verletzung

Polypektomie

- **Sessile Polypen 10 – 19 mm**

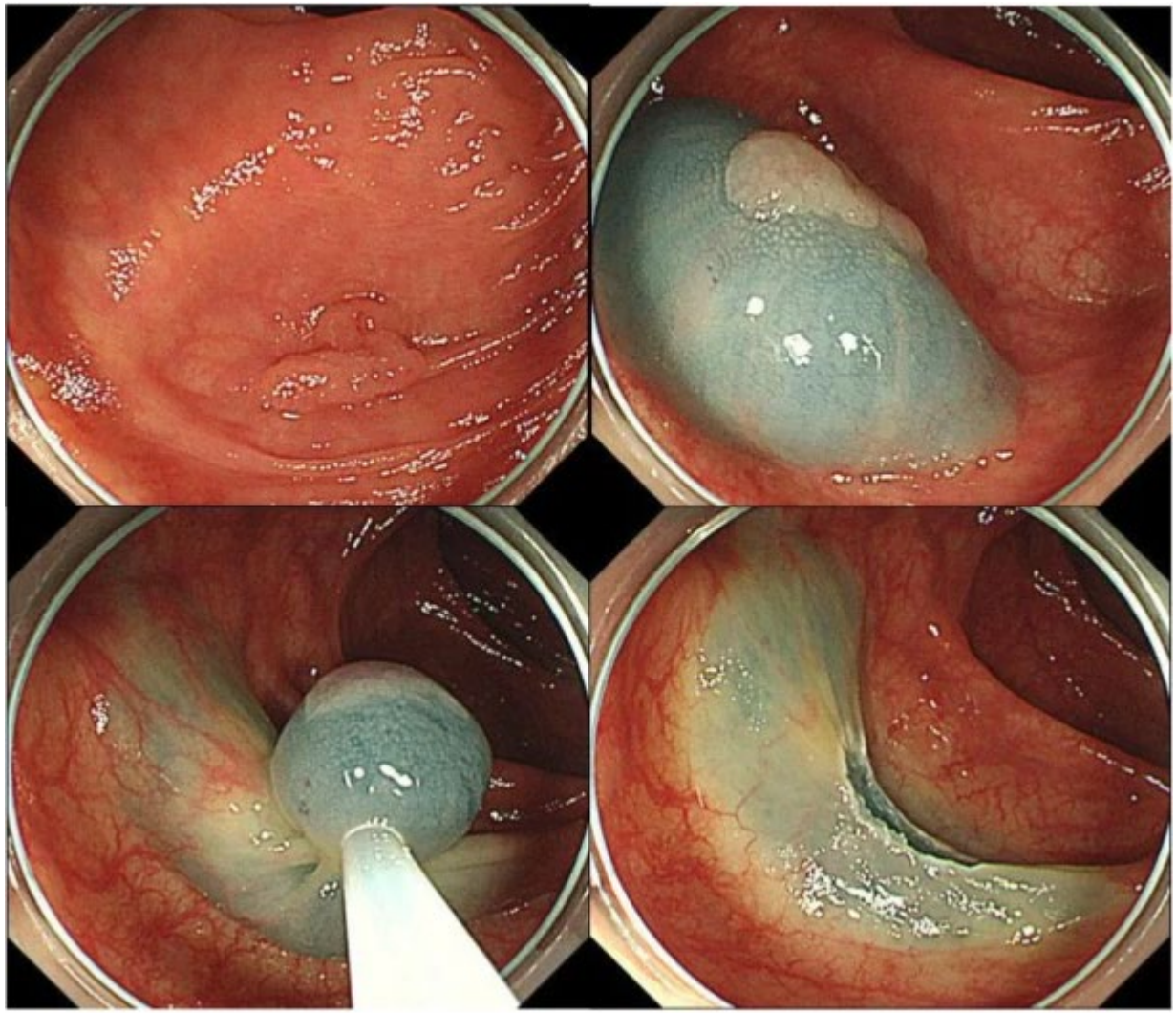

EMR/Polypektomie

- **Grosse (>= 20 mm) Polypen**

RECOMMENDATION

Large (≥ 20 mm) sessile and laterally spreading or complex polyps, should be removed by an appropriately trained and experienced endoscopist, in an appropriately resourced endoscopy center. (Moderate quality evidence, strong recommendation.)

EMR/Polypektomie

- **Grosse (>= 20 mm) Polypen**

RECOMMENDATION

ESGE recommends careful lesion assessment prior to EMR to identify features suggestive of poor outcome. Features associated with incomplete resection or recurrence include lesion size >40 mm, ileocecal valve location, prior failed attempts at resection, and size, morphology, site, and access (SMSA) level 4. (Moderate quality evidence; strong recommendation.)

EMR

EMR: Unterpritzung einer Lösung in die Submucosa, damit die mukosale Läsion von der darunter liegenden Muscularis propria getrennt wird

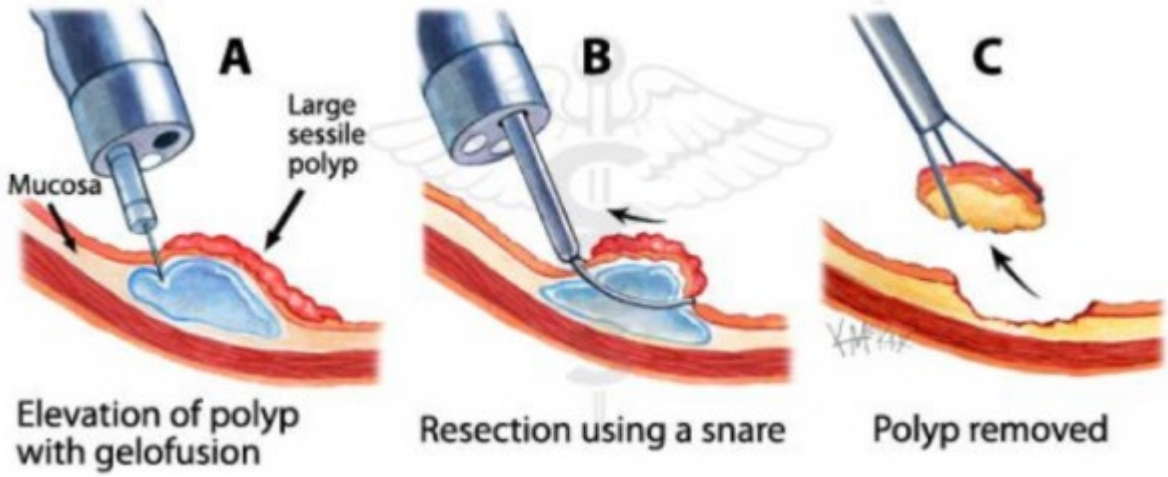

INSELSPITAL
Universitätsklinik für
Viszerale Chirurgie und Medizin

EMR/Polypektomie

- **Vorbereitung**
  - Idealerweise Positionierung der Läsion bei 6 Uhr
  - Insufflation mit CO2

RECOMMENDATION
ESGE suggests the use of carbon dioxide (CO_2) insufflation during colonoscopy and polypectomy. (Low quality evidence, strong recommendation.)

RECOMMENDATION
ESGE recommends the use of CO_2 insufflation for EMR. (Moderate quality evidence; strong recommendation.)

  - CO2 wird > 100x schneller als die Luft absorbiert
  - Reduziert die postinterventionellen Schmerzen
  - Reduziert das Perforationsrisiko bei EMR
  - Falls Perforation, Endoskopeur hat mehr Zeit zu behandeln

Bauchzentrum
BERN

EMR

- **Lösung zur Unterspritzung**

RECOMMENDATION

ESGE suggests the use of submucosal injectates for EMR that are more viscous than normal saline and whose safety has been proven, including succinylated gelatin, hydroxyethyl starch, or glycerol, since their use is associated with superior technical outcomes and reduced procedural time. (High quality evidence; weak recommendation.)

RECOMMENDATION

ESGE recommends that a biologically inert blue dye such as indigo carmine should be incorporated into the submucosal injection solution to facilitate identification of fluid cushion extent, lesion margins, and deep mural injury. (Moderate quality evidence; strong recommendation.)

EMR/Polypektomie

- **Schlingentypen**
  - Verschiedene Grösse und Formen (zirkulär, oval, hexagonal)
  - Monofile
    - Dünner Schlingendraht (< 0.4 mm) -> grössere Stromdichte -> schnellere Gewebedurchtrennung -> eine thermische Verletzung unwahrscheinlicher
  - Polyfile
    - Breiter Schlingendraht (0.4 mm – 0.5 mm) -> sie können die Schleimhautoberfläche besser anschleifen -> effektivere Resektion von flachen Polypen
  - **Keine klare Empfehlung; abhänging von der Grösse, Morphologie und Stelle des Polypen sowie von der Erfahrung des Endoskopeurs**

EMR/Polypektomie

- **Schlingentypen**

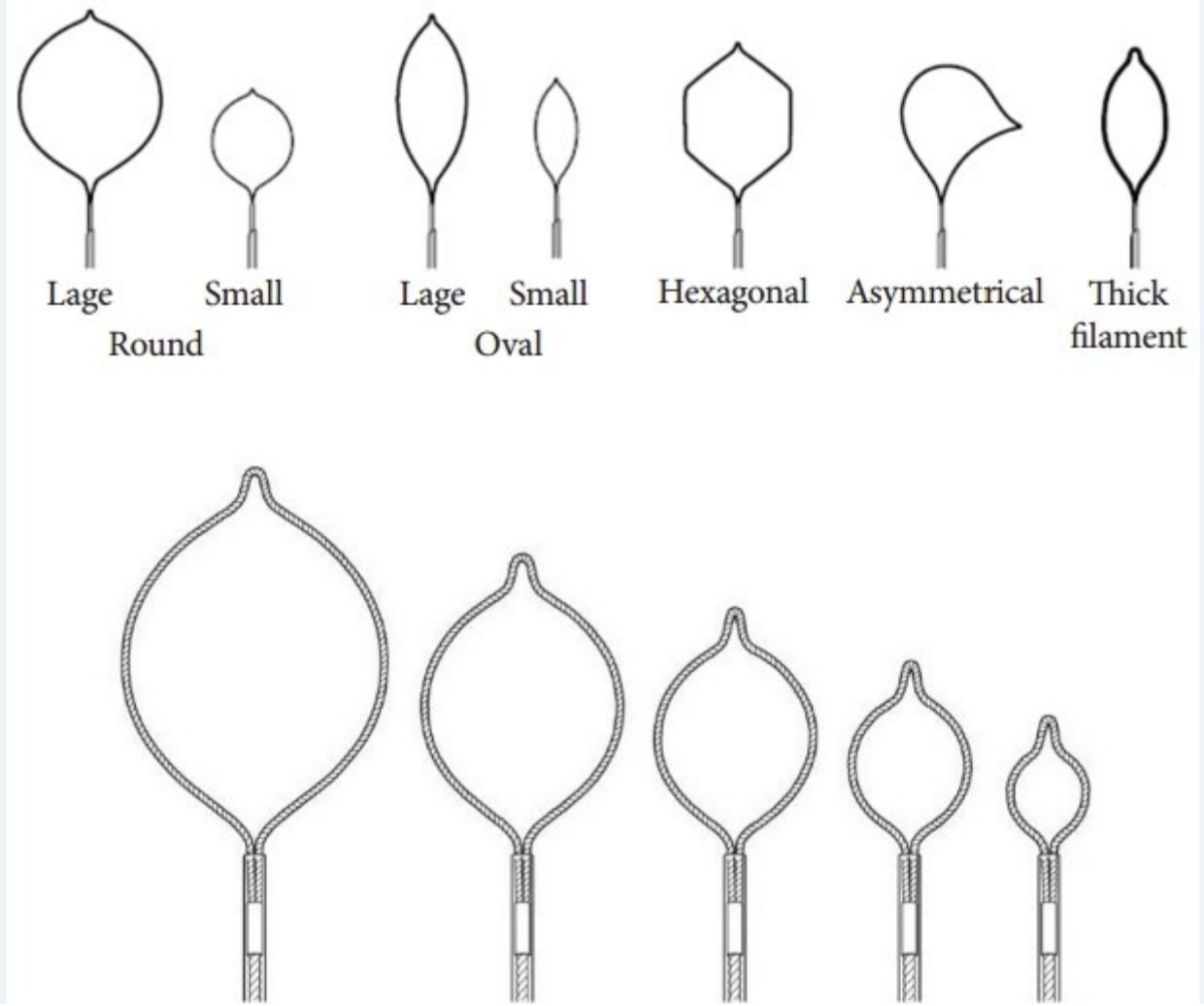

EMR

- **Goals**

RECOMMENDATION

ESGE recommends that the goals of EMR are to achieve a completely snare-resected lesion in the safest minimum number of pieces, with adequate margins, and without need for adjunctive ablative techniques. (Low quality evidence; strong recommendation.)

RECOMMENDATION

ESGE suggests that en bloc EMR should be limited to lesions ≤ 20 mm in the colon and ≤ 25 mm in the rectum. (Low quality evidence, weak recommendation.)

- **Wenn in Piece-Meal Technik -> Re-Koloskopie in 3-6 Monaten**

Modified EMR techniques

- **CAP-assisted EMR**
  - Eradikationsrate 91%
  - Komplikationssrate 10.2%

- **Underwater EMR**
  - En bloc Resektionsrate und komplette Resektion höher als in der klassischen EMR
  - Niedrige Komplikationsrate
  - Vielleicht geeignet für noch grössere Läsionen

EMR

- **Wenn Läsion nicht aufgehoben**
  - **Ursachen:**
    - Invasives Karzinom
    - Fibrose wegen Polypenprolaps
    - Früherer Polypektomieversuch
    - Reaktion auf die Lösung, die unterspritzt wurde
  - **Thermische Ablation oder Avulsion (Abriss) or further techniques (z.B. ESD, FTRD)**
    - Vollständige Resektion besser mit Alvusion als Ablation
    - Bevorzugt in schwierigen Stellen (IC-Klappe, Appendix, Angulation von Kolon)

16. Endoloop.gif

INSELSPITAL
Universitätsklinik für
Viszerale Chirurgie und Medizin

Polypektomie

- **Gestielte Polypen**

RECOMMENDATION

ESGE recommends HSP for pedunculated polyps. To prevent bleeding, in pedunculated colorectal polyps with head ≥ 20 mm or a stalk ≥ 10 mm in diameter, ESGE recommends pretreatment of the stalk with injection of dilute adrenaline and/or mechanical hemostasis. (Moderate quality evidence; strong recommendation.)

- **Mechanische Hämostase**
  - Endoloops
  - Clips

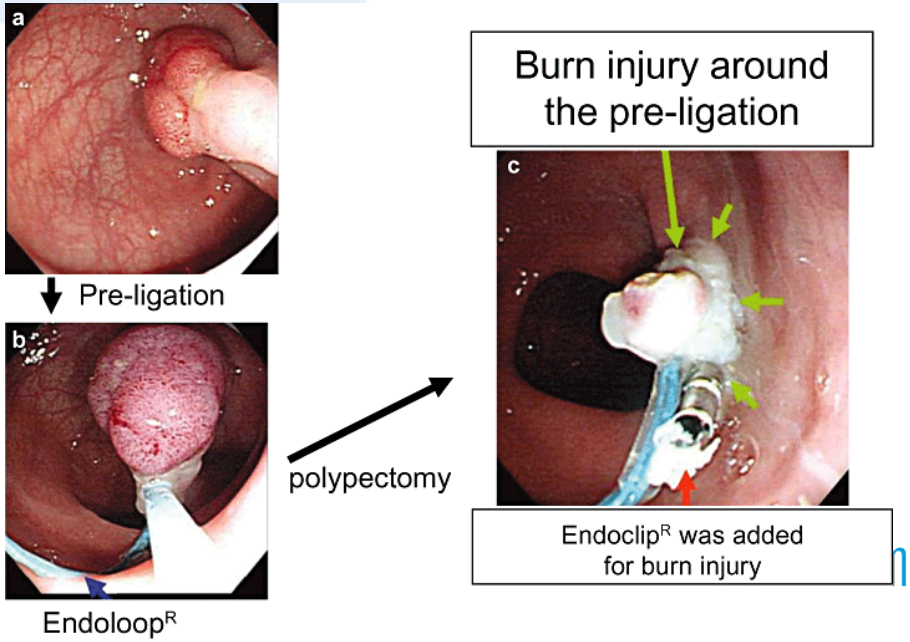

16. Endoloop.gif

INSELSPITAL
Universitätsklinik für
Viszerale Chirurgie und Medizin

Colonic tattooing

RECOMMENDATION

ESGE recommends that lesions that may need to be located at future endoscopic or surgical procedures should be tattooed during colonoscopy. (Low quality evidence, strong recommendation.)

RECOMMENDATION

ESGE recommends that tattoos be placed ≥ 3 cm anatomically distal (anal side) to the lesion, with 2 or 3 separate injections being made at this level on opposite sides of the lumen, to increase the likelihood of detection. Endoscopic and surgical team members should agree on a standardized location of tattoo injection at their institution. The details of tattoo injection should be clearly text- and photo-documented in the endoscopy report, using unambiguous terminology. (Low quality evidence; strong recommendation.)

Bauchzentrum
BERN

16. Endoloop.gif

INSELSPITAL
Universitätsklinik für
Viszerale Chirurgie und Medizin

Komplikationen

- **Blutung**
  - **Intrainterventionell:** während der Intervention, persistiert > 60 Sekunde oder erfordert endoskopische Intervention
  - **Postinterventionell:** innerhalb von 30 Tagen nach Polypektomie; erfordert notffallmässige Vorstellung, Hospitalisation oder Re-Intervention

- **Perforation**

- **Postpolypektomie-Syndrom**

  - **Dokumentation von Komplikationen**

RECOMMENDATION
ESGE recommends audit of adverse events. (Moderate quality evidence; strong recommendation.)

Bauchzentrum
BERN

16. Endoloop.gif

INSELSPITAL
Universitätsklinik für
Viszerale Chirurgie und Medizin

Komplikationen: Blutung

Intrainterventionelle Blutung

- 2.8% der Polypektomien, 6.5 – 11.3% für EMR von Läsionen > 20 mm

- **Risikofaktoren:**
  - Polypengrösse
  - Rechtsseitiges Kolon
  - Paris IIa oder Is
  - Tubulovillöse Adenome
  - Endoskopieerfahrung

Bauchzentrum BERN

16. Endoloop.gif

INSELSPITAL
Universitätsklinik für
Viszerale Chirurgie und Medizin

Komplikationen: Blutung

Intrainterventionelle Blutung

- **Behandlung**
  - Snare-tip soft coagulation
  - Coagulating forceps
  - Clips
  - **Für gestiellte Polypen:** Clips oder Endoloop
  - (OTSC)
  - Adrenalin 1:10’000

Bauchzentrum
BERN

INSELSPITAL
Universitätsklinik für
Viszerale Chirurgie und Medizin

Komplikationen: Blutung

Postinterventionelle Blutung

- 6% für EMR von Läsionen > 20 mm

- **Risikofaktoren:**
  - Alter > 65
  - Antikoagulants
  - Rechtsseitiges Kolon

- **Behandlung**
  - Konservativ (bis 55%)
  - Re-Koloskopie und Blutstillung
  - Selten Angiographie oder Operation

16. Endoloop.gif

INSELSPITAL
Universitätsklinik für
Viszerale Chirurgie und Medizin

Komplikationen: Blutung

Prophylaktisches Clipping

RECOMMENDATION

ESGE suggests that there may be a role for mechanical prophylaxis (e.g. clip closure of the mucosal defect) in certain high risk cases after polypectomy or EMR. This decision must be individualized based on the patient's risk factors. (Low quality evidence; weak recommendation.)

- Merkmale von Polypen (Grösse, Morphologie, Lokalisation)
- Alter > 65
- Komorbidität: arterielle Hypertonie, chronische Nierenerkrankung, Antikoagulation

Bauchzentrum BERN

16. Endoloop.gif

INSELSPITAL
Universitätsklinik für
Viszerale Chirurgie und Medizin

Komplikationen: Perforation

- 1-2 % aller Polypektomien

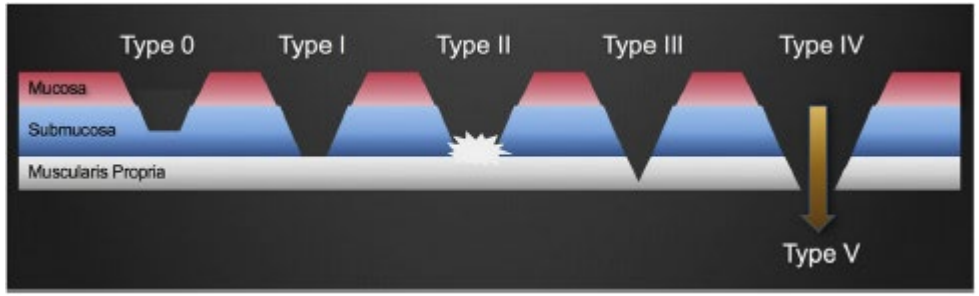

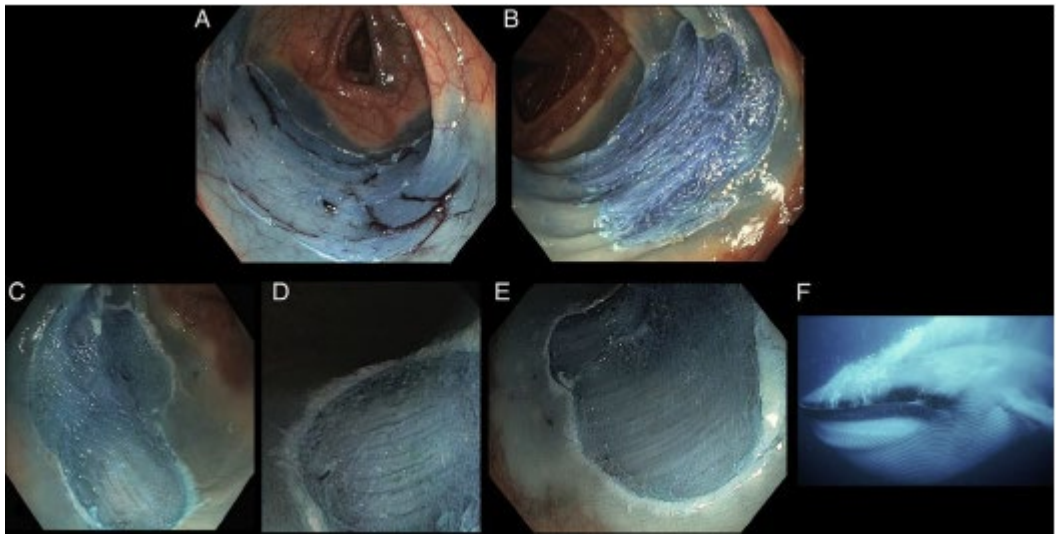

Bauchzentrum
BERN

16. Endoloop.gif

INSELSPITAL
Universitätsklinik für
Viszerale Chirurgie und Medizin

Komplikationen: Perforation

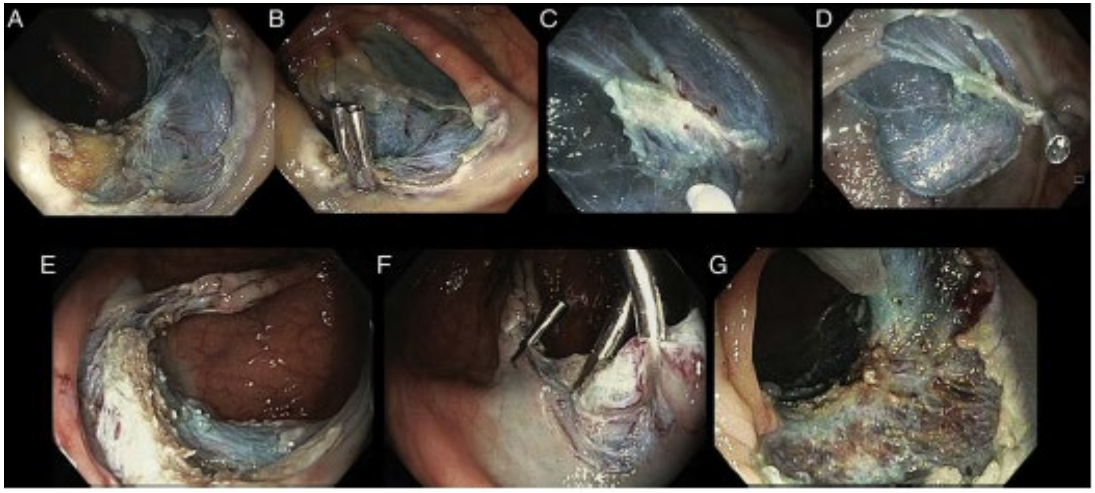

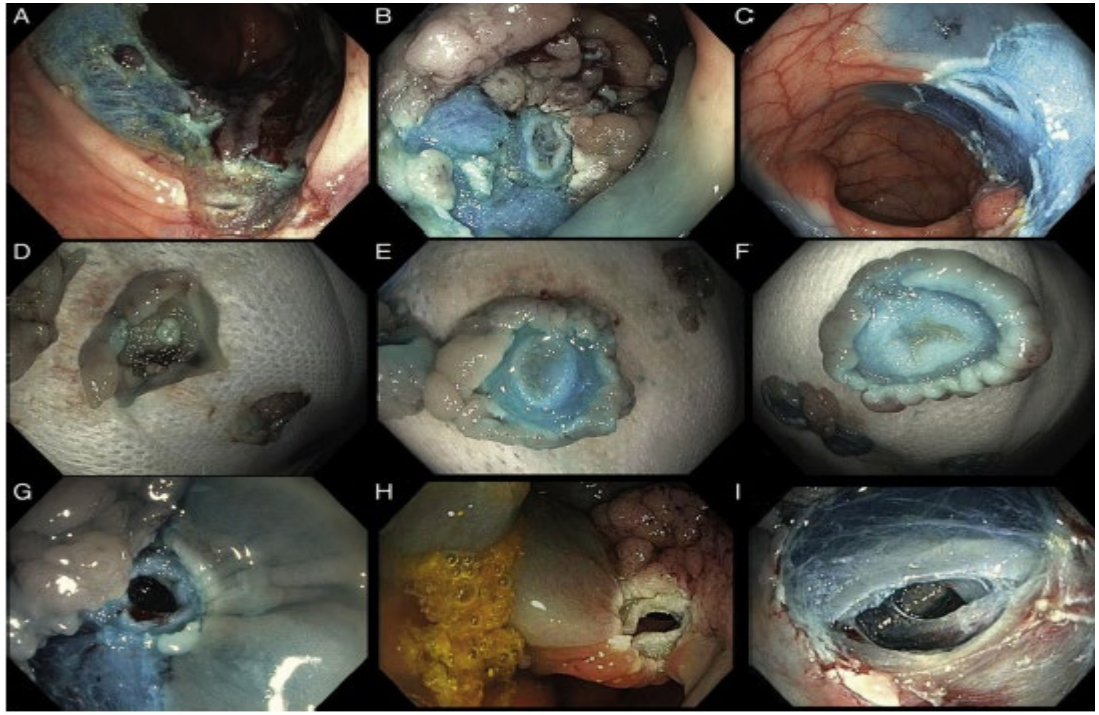

Bauchzentrum
BERN

16. Endoloop.gif

INSELSPITAL
Universitätsklinik für
Viszerale Chirurgie und Medizin

Komplikationen: Perforation

- **Behandlung**
  - Clips
  - OTSC
  - Operation

- **Prophylaktisches Clipping?**
  - <u>Endoscopische Zeichen:</u>
    - Sichtbare Muscularis Propria
    - Submukosales Fett

RECOMMENDATION

ESGE recommends careful inspection of the post-resection mucosal defect to identify features of or risk factors for impending perforation. Where these risk factors are identified, clip closure should be performed. (Moderate quality evidence; strong recommendation.)

Bauchzentrum BERN

16. Endoloop.gif

INSELSPITAL
Universitätsklinik für
Viszerale Chirurgie und Medizin

Komplikationen: Postpolypektomie-Syndrom

- Tiefe thermische Verletzung der Kolonwand, die eine seröse Inflammation verursacht hat
- **Inzidenz:** 1 % (0 – 7.6 %)
- **Klinik:** lokale Bauchschmerzen, Fieber, Peritonitiszeichen, erhöhte Infektparameter, **radiologisch Ausschluss Perforation**
- **Behandlung:**
  - Bowel rest
  - Intravenöse Flüssigkeit
  - Antibiotische Therapie

Bauchzentrum BERN

Schlingenpolypektomie/EMR (Kolon)

Danke für die Aufmerksamkeit